

Surgical Management of Tuberculous Vertebra Plana of the Third Cervical vertebra: A Case report.

Dhiraj V Sonawane¹, Bipul Kumar Garg¹, Harshit Dave¹, Shrikant Savant¹

Abstract

Tuberculosis disease is commonly caused by Mycobacterium tuberculosis. The higher incidence and prevalence of tuberculosis is a common health problem particularly in developing countries. Spinal tuberculosis usually represents at advanced levels and diagnosis of this disease is not easy. Patients with spinal tuberculosis usually present with gibbus formation, back ache, low grade fever, neurological symptoms and deficits. Although, commonly seen in dorsal spine lesions, cervical and cervico-thoracic lesions with spine tuberculosis rarely seen in literature. Isolated tuberculosis of cervical spine is a rare entity and accounts for incidence of 3 to 5 percent. Early clinical diagnosis and management is great challenge in toddler group. Herein, we would like to present a 12 year old patient of C3 vertebral body tuberculosis with 90 percent collapse with neurological deficits and its management.

Keywords: vertebrae plana, tuberculosis, cervical spine

Introduction:

Tuberculosis (TB) disease is commonly caused by Mycobacterium tuberculosis[1]. The higher incidence and prevalence of TB is a common health problem in developing countries[1] The bone structure particularly dorsal spine is the most common extra pulmonary area for TB after lymph nodes[1]. The first modern description of spinal TB was defined by Sir Percival Pott in 1779[2]. Spinal TB usually presents at advanced levels and diagnosis of this disease is not easy; the late diagnosis and management of disease causes higher rate of spinal cord compression and deformities[2]. Patients with spinal TB usually represent with gibbus formation, back ache, low grade fever,

neurological symptoms and deficits.[1] Herein, we would like to present an unusual case of cervical spine TB with neurological deficits and its management.

Case Report:

A 12-year-old girl presented to a tertiary care centre with a 10-week history of pain, neck stiffness and malaise. On extracting history from the patient, she denied any history of previous trauma to head or neck or pain in other joints. There was evening rise of fever with weight loss and loss of appetite; No dysphagia, hoarseness of voice or any an occipital headache was noted.


A BCG immunization scar was seen and there was no koch contact. Rest of her systems examination were

normal. Local deep tenderness was present below the spinous process of the second cervical vertebrae. Paraspinal spasm was observed at the upper cervical region with no lymphadenopathy. On neurological examination, MRC grade 5 at all four limbs and no sensory loss was noted. Muscle tone, Deep tendon reflexes were normal with tandem gait and Romberg test negative. Plain radiographs[Fig 1] of the cervical spine on the lateral view showed the partial destruction of the C3 vertebra with angular kyphosis. MRI[Fig 2] showed 90% destruction of the C3 vertebral body with abscess seen anteriorly in the pre and paravertebral spaces without significant cord compression and involvement of C2-3 facet suggestive

of tuberculosis of C3 body and no involvement of C2-C3 and C3-C4 discs. Plain radiograph of the chest was normal with no nodular lesions. Sputum for tuberculosis was negative. On blood

¹Sir J.J. Group of Hospitals, Byculla Mumbai(400001).

Address of Correspondence
Dr. Bipul Kumar Garg,
Assistant Professor, Dept of Orthopaedics,
J.J. Group of Hospitals Mumbai.
Email id: garg.bipul@gmail.com



Dr Dhiraj Sonawane



Dr Bipul Garg



Dr Harshit Dave



Dr Shrikant Savant

© 2019 by International Journal of Spine | Available on www.ijsonline.co.in | doi:10.13107/ij.s.2456-1177.533
This is an Open Access article distributed under the terms of the Creative Commons Attribution Non-Commercial License (<http://creativecommons.org/licenses/by-nc/3.0>) which permits unrestricted non-commercial use, distribution, and reproduction in any medium, provided the original work is properly cited.

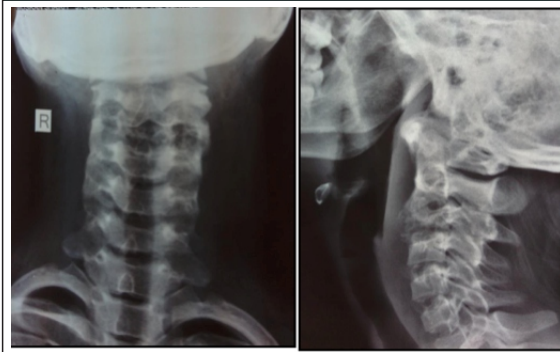


Figure 1: Anteroposterior and Lateral X ray of Cervical Spine showing destruction of C3 Vertebral body

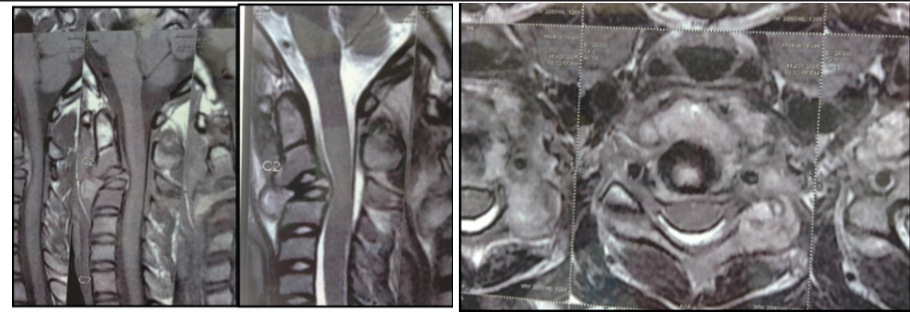


Figure 2: MRI Cervical spine- T1W and T2W Saggital images and Axial image showing 90% collapse of C3 body, Kyphotic deformity, Anterior Epidural Abscess, Prevertebral abscess at C2, C3, C4 Levels

investigation Haemoglobin was 8.8 g/dl, Lymphocytosis and ESR was 85 at the end of one hour was noted. HIV test was negative. Montoux test and TB GOLD test was negative.

Patient denied consenting for biopsy of the lesion understanding the high risk of the procedure and the technical challenges associated with the difficult area of approach. The patient was given a trial of conservative management. In absence of tissue culture and histological evidence, an empirical course of quadruple antitubercular drug regimen (3HRZE and 12HR) was started. Cervical traction of 10 pounds was given with Halter traction to prevent the collapse of disease vertebra. The patient was kept under observation for the first 6 weeks. At the end 6 weeks of antitubercular drug therapy, radiographs showed worsening kyphosis with vertebra plana. On clinical examination, she presented with

MRC grade 4 power in her upper limbs with spasticity in her upper limbs and exaggeration of the all the deep tendon reflexes. Surgical management was planned considering worsening neurology and kyphosis. After general anesthesia patient was positioned supine for anterior cervical approach, gardener wells tongs with 10 pounds weight was applied to achieve cervical lordosis with 20-degree rotation on the right side. Shoulder strapping was applied and interscapular rolled towel was kept. Incision site was marked under fluoroscopy, high anterior cervical approach was taken from the left side. A transverse incision was taken from midline to posterior border of sternocleidomastoid. Then platysma was split longitudinally. Gently retract sternocleidomastoid laterally and sternohyoid and sterniothyroid step muscle with trachea and oesophagus medially. Carotid artery palpated and plane was developed between medial edge of carotid sheath and structure retracted medially. Level reconfirmed under fluoroscopy and longus coli was elevated, abscess and infected granulation tissue from the third cervical vertebra were sent for culture and histopathological examination. C3 Total corpectomy was done and adjacent discs above and below C3 were removed, C2 and C4 endplate prepared. Lamina spreader was inserted between C2 and C4 and traction was

. Distraction cause opening of space mm to 15mm. Tricortical iliac crest 15mm was harvested and inserted C2-4 and stabilisation was done with profile anterior cervical plate. Intraoperative events and the early post-operative period were uneventful. There was no dysphagia or hoarseness of voice or noticed even in the delayed post-operative period. Patient was mobilised on the post-operative day with Philadelphia collar. The pathologist reported the sample granuloma and giant cells and the isolating Mycobacterium tubercle confirmed the diagnosis of tuberculosis. Genetic suggested sensitivity to isoniazid and rifampicin. The patient was mobilised with Philadelphia collar for 3 months. The patient was advised to continue the Antitubercular drug regimen for 15 months, CT scan on completion Anti Tubercular Treatment showed solid fusion with complete incorporation of the graft[Fig 3]. At follow-up of 4 years the patient's neurology was normal, range of motion of cervical spine was functionally acceptable[1]

increased to 20 pounds to achieve more distraction

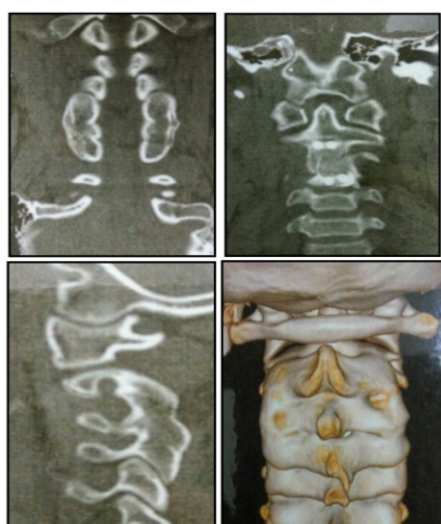

Figure 3: Coronal, Parasagittal and 3D reconstruction CT images showing Complete fusion between lateral masses of C2 C3 and C4 and complete fusion of iliac crest bone graft with C2 and C4 endplates anteriorly

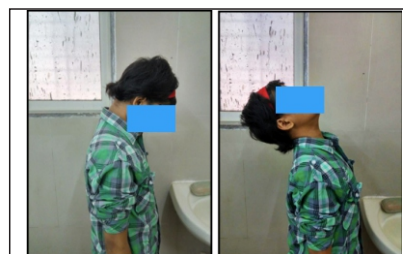

Figure 4: Showing complete flexion and extension at 4 years of follow up

D i s c u s s i o n
In many parts of the world, TB is a growing health problem particularly in developing countries and also increasing in developed countries[3] This disease is the leading infectious situation in the world and is responsible for more than 2 million deaths[6]. The incidence of spinal tuberculosis with neurological involvement is between 10-100% and it commonly leads to neurological sequelae if not treated sufficiently[3,4]. TB is especially responsible for 1-3% of all infectious cases and accounts for 40% of all infections [

Because of the slow growth rate of the *Mycobacterium tuberculosis*, isolation, identification, and drug susceptibility testing of this organism can take several weeks or longer[6]. Many molecular methods have been developed for direct detection, species identification, and drug susceptibility testing of this organism and these new methods can potentially reduce the diagnostic time[6]. In recent years, two nucleic acid amplification methods, the Enhanced *Mycobacterium tuberculosis* Direct Test (Gen-Probe) and the Amplicor *Mycobacterium tuberculosis* Test (Roche Diagnostic Systems), have been approved by the Food and Drug Administration (FDA) for direct detection of *M. Tuberculosis*[6]. PCR-based sequencing has become commonly used to identify many mycobacterial species and DNA probes have been widely used for species determination of the most commonly encountered mycobacteria [6]. Although, commonly seen in dorsal spine lesions, cervical and cervico-thoracic lesions with spine TB are rarely seen in literature and these cervical-upper thoracic spinal cord lesions with TB are prone to be compressed[4]. In our case, spine TB abscess was located in C3 cervical and paravertebral area. Hu et al reported a 43-year-old man with a huge retropharyngeal abscess causing airway and oesophageal obstruction associated with cervical spine TB and

also they indicated that cervical spine TB is a rare condition, accounting for 3-5% of spinal TB[5]. Alam et al reported a 38-year-old female with Pott's C6 and C7 quadriplegia with bowel bladder involvement in their multi centre study[2]. Her pretreatment MRI demonstrated destruction of C6- C7 vertebrae and compression of spinal cord. Anterior surgical decompression by corpectomy was performed to her[2]. After four months, she was able to regain movement with relieved pain. In the follow-up period, there was no recurrence of TB. Conservative first line therapies treatment such as anti-TB drugs, anti-TB chemotherapy and surgery are treatment options of spinal TB[2]. Surgical procedure should be considered patients with extensive spine involvement, severe deformity, vertebral body collapse, prevertebral cervical abscess, advanced neurological involvement and any sign of progressive recovery despite of conservative therapy [2].

C o n c l u s i o n : Isolated tuberculosis of cervical spine is a rare entity and accounts for incidence of 3 to 5 percent. If not diagnosed and treated properly, it can lead to devastating complications like neurodeficit and deformity. Tuberculosis is still believed to be a medical condition unless proven instability or neurological deterioration is observed. Good results are observed with surgery and

chemotherapy as well as chemotherapy alone.

References

1. Di Lorenzo N, Fortuna A, Guidetti B : Craniovertebral junction malformations. Clinoradiological findings, long-term results, and surgical indications in 63 cases. *J Neurosurg* 57 : 603-608, 1982
2. Seung Won Choi, Han Yu Seong,, Sung Woo Roh. Case report - Spinal Extradural Arachnoid Cyst, *J Korean Neurosurg Soc* 54: 355-358, 2013
3. Netra R, Min L, Shao Hui M, Wang JC, Bin Y, Ming Z : Spinal extradural meningeal cysts : an MRI evaluation of a case series and literature review. *J Spinal Disord Tech* 24 : 132-136, 2011
4. Elsberg CA, Dyke CG, Brewer ED: The symptoms and diagnosis of extradural cysts. *Bull Neurol Inst NY* 3:395-417, 1934
5. Bergland RM: Congenital intraspinal extradural cyst. Report of three cases in one family. *J Neurosurg* 28:495-499, 1968
6. Yabuki S, Kikuchi S: Multiple extradural arachnoid cysts: report of two operated cousin cases. *Spine (Phila Pa 1976)* 32:E585-E588, 2007
7. Lee CH, Hyun SJ, Kim KJ, Jahng TA, Kim HJ : What is a reasonable surgical procedure for spinal extradural arachnoid cysts : is cyst removal mandatory? Eight consecutive cases and a review of the literature. *Acta Neurochir (Wien)* 154 : 1219-1227, 2012
8. Oh JK, Lee DY, Kim TY, Yi S, Ha Y, Kim KN, et al. : Thoracolumbar extradural arachnoid cysts : a study of 14 consecutive cases. *Acta Neurochir (Wien)* 154 : 341-348; discussion 348, 2012
9. Hyndman OR, Gerber WF: Spinal extradural cysts, congenital and acquired; report of cases. *J Neurosurg* 3:474-486, 1946
10. Aaron E. Bond, Gabriel Zada, Ira Bowen, J. Gordon McComb, and Mark D. Krieger,; Spinal arachnoid cysts in the pediatric population: report of 31 cases and a review of the literature, *J Neurosurg Pediatrics* 9:000-000, 2012
11. McCrum C, Williams B: Spinal extradural arachnoid pouches. Report of two cases. *J Neurosurg* 57:849-852, 1982

12. Sandberg DI, McComb JG, Krieger MD: Chemical analysis of fluid obtained from intracranial arachnoid cysts in pediatric patients. *J Neurosurg* 103 (5 Suppl):427–432, 2005
13. Nabors MW, Pait TG, Byrd EB, Karim NO, Davis DO, Koblina AI, et al. : Updated assessment and current classification of spinal meningeal cysts. *J Neurosurg* 68 : 366-377, 1988
14. Perret G, Green D, Keller J: Diagnosis and treatment of intradural arachnoid cysts of the thoracic spine. *Radiology* 79: 425–429, 1962
15. Rabb CH, McComb JG, Raffel C, Kennedy JG: Spinal arachnoid cysts in the pediatric age group: an association with neural tube defects. *J Neurosurg* 77:369–372, 1992
16. Cloward RB: Congenital spinal extradural cysts: case report with review of literature. *Ann Surg* 168:851–864, 1968
17. Kriss TC, Kriss VM: Symptomatic spinal intradural arachnoid cyst development after lumbar myelography. Case report and review of the literature. *Spine (Phila Pa 1976)* 22:568– 572, 1997
18. De Oliveira RS, Amato MC, Santos MV, Simão GN, Machado HR.: Extradural arachnoid cysts in children. *Childs Nerv Syst.* 2007 Nov;23(11):1233-8.
19. Ertan Ergun, Alp OzgunBorcek, Berker Cemil, Fikret Dogulu, M. Kemal Baykaner: Should We Operate all Extradural Spinal Arachnoid Cysts? Report of a Case, *Turkish Neurosurgery* 2008, Vol: 18, No: 1, 52-55
20. Lee SH, Shim HK, Eun SS.: Twist technique for removal of spinal

Conflict of Interest: NIL
Source of Support: NIL

How to Cite this Article

Sonawane DV, Garg BK, Dave H, Singh V, Chandanwale A. Multiple Spinal Extradural Arachnoid Cyst : A Case Report. *International Journal of Spine* Jan-June 2019;4(1):31-34 .